



## Comparison of the Effects of Hypercholesterolemic Diets in Biochemical Outcomes of Myocardial Infarction in Rats

Arash Khorrami <sup>1,2</sup>, Alireza Garjani <sup>3</sup>, Bahador Bagheri <sup>4</sup>, Nasrin Maleki-Dizaji <sup>3</sup>, Mojtaba Ziaee <sup>5,6,\*</sup>

<sup>1</sup> Department of Basic Science, School of Nursing and Midwifery, Maragheh University of Medical Sciences, Maragheh, IR Iran

<sup>2</sup> Phytopharmacology Research Center, Maragheh University of Medical Sciences, Maragheh, IR Iran

<sup>3</sup> Department of Pharmacology, Tabriz University of Medical Sciences, Tabriz, IR Iran

<sup>4</sup> Cancer Research Center and Department of Pharmacology, Faculty of Medicine, Semnan University of Medical Sciences, Semnan, IR Iran

<sup>5</sup> Medicinal Plants Research Center, Institute of Medicinal Plants, ACECR, Karaj, IR Iran

<sup>6</sup> Cardiovascular Research Center, Madani Hospital, Tabriz University of Medical Sciences, Tabriz, IR Iran

### ARTICLE INFO

#### Article Type:

Research Article

#### Article History:

Received: 20 Jan 2017

Revised: 17 Dec 2017

Accepted: 23 Dec 2017

#### Keywords:

Dietary Cholesterol  
 Myocardial Infarction  
 Low Density Lipoprotein  
 Rat

### ABSTRACT

**Background:** Saturated fatty acids and high sugar consumption along with sedentary lifestyle increase. The prevalence of atherosclerotic cardiovascular disease.

**Objectives:** In the present study, dietary high cholesterol and oxidized cholesterol implications after myocardial infarction induced by Isoproterenol compared with myocardial infarction subjects with normal diet were studied.

**Materials and Methods:** 36 animals were allocated randomly in 6 groups; three groups were fed with standard, high-cholesterol or high-oxidized cholesterol diets for 14 weeks. The other three groups received the same diets as well as ISO to induce acute MI. Lipid profile, OxLDL and total antioxidant levels were measured in the serum. The myocardial CoQ10 content was analyzed using a validated RP-HPLC. The infarct size was determined using triphenyl tetrazolium chloride staining. Histological changes and necrosis were evaluated using microscopic analysis.

**Results:** Malondialdehyde concentration and infarct size in all high fat-fed groups were increased compared to the control group, especially in the ISO-induced MI groups. The total antioxidant level was decreased in both ISO-induced MI treated groups. CoQ10 content of the myocardium in control group ( $4.45 \pm 0.19 \mu\text{g}/100 \text{mg}$ ) was significantly higher than cholesterol-fed ( $2.99 \pm 0.05 \mu\text{g}/100\text{mg}$ ,  $P < 0.001$ ) and oxidized Cholesterol-fed ( $1.42 \pm 0.06 \mu\text{g}/100\text{mg}$ ,  $P = 0.001$ ) groups. This reduction was more intense in the ISO-induced MI groups compared to the ISO group. High cholesterol and oxidized cholesterol diets increased the isoproterenol-induced necrosis in the myocardium ( $P < 0.05$ ,  $P < 0.01$ , respectively) compared to the rats taking normal diet.

**Conclusions:** Overall, we concluded that the expansion of the infarct size and reduction of the CoQ10 content in the rat's myocardium occurred as a result of elevated level of high serum level of OxLDL rather than non-oxidized LDL.

### 1. Background

Coronary artery disease (CAD) and acute myocardial infarction (AMI) are the leading cause of total global mortality and morbidity (1). The most important cause of an increased prevalence of atherosclerotic cardiovascular disease is overconsumption of saturated fats and sugar, along with a sedentary lifestyle (2). Diet-induced

hypercholesterolemia has increased detrimental effects such as oxidative stress (3), inhibition of nitric oxide synthesis (4), LDL conversion to oxidized LDL (OxLDL) leading to vascular occlusion, and apoptosis on the myocardium (5).

Dietary oxidized cholesterol is absorbed from the gut and passed into the circulatory system via chylomicron/chylomicron residues, thus, shifting to endogenously synthesized LDL and HDL cholesterol (6). Exposure of LDL particles to reactive oxygen species (ROS) and reactive nitrogen species (RNS) besides inadequate antioxidant capacity lead to lipid peroxidation which

\*Corresponding author: Mojtaba Ziaee, Medicinal Plants Research Center, Institute of Medicinal Plants, ACECR, Karaj, Iran, Tel: +98-2166561470, E-mail: Ziaee@imp.ac.ir.

generates a number of relatively toxic endproducts, such as malondialdehyde (MDA) 4-hydroxy-2-nonenal (HNE), 2-propenal (acrolein), and isoprostanes (7). Coenzyme Q10 (CoQ10) is an efficient endogenous scavenger that is related to low density lipoproteins and detoxifies the generated free radicals, such as ROS (8). CoQ10 protects lipids against peroxidative damage. It scavenges the superoxide anion as well as peroxides.

## 2. Objectives

Our study was designed to evaluate the effects of oxidized cholesterol in the rats with myocardial infarction.

## 3. Materials and Methods

### 3.1. Experimental Protocol

In this experimental study, we used ISO-induced MI model (a reliable non-invasive standardized model of MI) (9) and a 2% cholesterol-rich diet or 2% oxidized cholesterol-rich diet for the rats for 14 weeks.

Thirty six male Wistar rats (body weight= 220 - 250 g, 8 weeks of age) were maintained at standard condition. The experimental diets were administered at 10 weeks of age for 14 weeks. All these experiments were approved by the animal care committee at Tabriz University of Medical Sciences.

Rats were randomly divided into six groups. In three groups, the animals were fed with standard diet, cholesterol-rich diet with the following composition: lard oil (15%), cholesterol (2%), cholic acid (0.25%), rodent chow powder (62.75%), wheat flour (10%), sucrose (10%) and oxidized Cholesterol-rich diet which was the same as the second group's diet, but cholesterol had been replaced with oxidized cholesterol. Oxidized cholesterol was prepared by the method described by IlonaStaprans (10).

Other study groups received Isoproterenol (Sigma Co; USA) for two consecutive days (100 mg/kg, dissolved in normal saline; S.c) at an interval of 24 hrs following 14 weeks feeding with three mentioned diets to induce acute MI. On the third day, serum samples were separated and stored at  $-80^{\circ}\text{C}$  for subsequent analysis. The heart samples were excised, washed with ice-cold normal saline, frozen in liquid nitrogen for 10 seconds, and then stored at  $-80^{\circ}\text{C}$  for later measurement of CoQ10 content.

### 3.2. Serum Biochemical Analysis

Serum samples were analyzed using enzymatic colorimetric methods for lipid profile, using commercially available kits (Pars Azmoon Laboratories, Iran). The assays were performed according to the manufacturer's instructions in duplicate. OxLDL level was measured using the OxLDL ELISA kits purchased from Glory Company.

### 3.3. Determination of Lipid Peroxidation in Myocardium

Concentration of malondialdehyde (MDA), a thiobarbiturate reactive substance, was measured as a marker of oxidative stress in the myocardial homogenates, using the method prescribed by Satoh (11). The lipid peroxidation was measured spectrophotometrically and expressed as nanomoles of MDA per gram of the heart tissue.

### 3.4. Determination of Total Antioxidant Status

Serum total antioxidant status (TAS) was measured by a commercially available kit from Randox Laboratories according to the manufacturer's instructions.

### 3.5. Measurement of Myocardial Infarct Size

A separate group of rats having the same characteristics as the other assay members were subjected to the infarct size measurement according to previously described method presented by Khalil (12).

### 3.6. CoQ10 Measurement in Heart Tissue

To evaluate the CoQ10 content, we sampled the heart tissues from frozen left ventricles and subjected the extraction process of CoQ10 which was done according to our previously described method (13).

### 3.7. Histopathological Examination

A separate group of rats fed with cholesterol and oxidized cholesterol-rich diets and treated with isoproterenol was prepared for the histopathological examination. The cardiac apex was cleaved and fixed in neutral buffered formalin. The tissues were embedded in paraffin, sectioned at  $5\ \mu\text{m}$ , and stained with hematoxylin and eosin (H&E) for evaluation of necrosis. Myocardial necrosis was evaluated in each section of the heart tissue, using a morphometric point-counting procedure. Histopathological changes were graded as 1, 2, 3, and 4 for low, moderate, high, and intensive pathological changes by two pathologists, respectively.

## 4. Results

### 4.1. Effects of Dietary Cholesterol and Oxidized Cholesterol on Lipid Profile, Peroxidation and Total Antioxidant Status

Table 1 shows a summary of the lipid profile, lipid peroxidation and total antioxidant status in the serum of rats following 14 weeks feeding with high cholesterol and normal diets. The levels of serum LDL, total cholesterol and triglycerides show a significant increase (2 - 3 folds) in both groups fed with cholesterol-rich and oxidized cholesterol-rich diets (with or without MI) compared to the control group ( $P < 0.001$ ). Although the increase in the serum level of HDL in cholesterol-fed rats was not significant compared to the control animals ( $P = 0.157$ ), feeding with oxidized cholesterol significantly increased the HDL level ( $P = 0.004$ ). ISO injection had no effect on the serum level of lipid profile. As shown in Figure 1, the serum concentrations of oxidized cholesterol were significantly high in both cholesterol and oxidized cholesterol-fed rats. However, the increase in oxidized cholesterol fed animals was much higher than the non-oxidized cholesterol group ( $P < 0.001$ ).

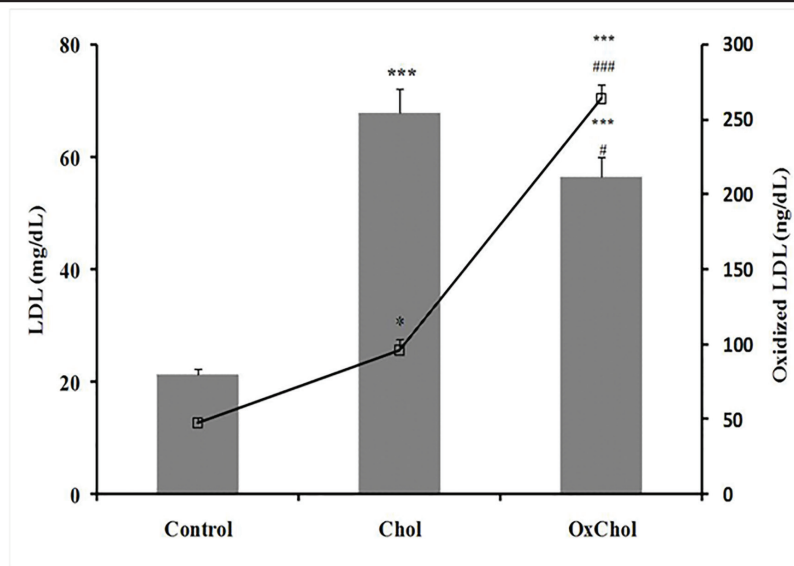
The obtained data showed that total antioxidant levels in the oxidized cholesterol ( $P < 0.001$ ), cholesterol+ISO ( $P < 0.001$ ) and oxidized cholesterol+ISO ( $P < 0.001$ ) groups were significantly lower than those in the control group. However, feeding with cholesterol-rich diet and rats receiving isoproterenol did not decrease the total antioxidant level in healthy animals ( $P = 0.130$ ,  $P = 0.065$ ), (Table 1).

To determine the lipid peroxidation, we measured

**Table 1.** Lipid Profile, Total Antioxidant Status in the Blood Serum and Malondialdehyde (MDA) Concentration in the Heart Tissue of Rats Fed with Normal Diet (Control), Cholesterol (Chol) and Oxidized Cholesterol (OxChol)-Rich Diets with or without Isoproterenol (ISO) Induced Myocardial Infarction

Variable	Control	Chol	OxChol	ISO	Chol+ISO	OxChol+ISO
Total cholesterol (mg/dL)	66.3 ± 4.5	126.2 ± 7 ***	133.5 ± 7 ***	68.3 ± 4	120.4 ± 8.3 ***	121.5 ± 8 ***
LDL (mg/dL)	21.2 ± 1.1	56.8 ± 4.3 ***	67.4 ± 3.5 ***	19.8 ± 1.5	60.6 ± 4 ***	55.2 ± 4 ***
Triglycerides (mg/dL)	58.3 ± 4	97.1 ± 5 ***	101.5 ± 6.5 ***	60.5 ± 4	99.1 ± 7.5 ***	108 ± 8 ***
HDL (mg/dL)	34 ± 3.8	46 ± 2.5	51.8 ± 2.5 *	39.6 ± 3	45.8 ± 2.7	49.6 ± 2.6 *
Total antioxidant(nmol/L)	1.29 ± 0.08	1.12 ± 0.09	0.85 ± 0.06 **	1.08 ± 0.08 *	0.99 ± 0.08 **, †	0.81 ± 0.04 **, ††, #
MDA (nmol/g tissue)	30.8 ± 1.8	43 ± 2.1 *	60.8 ± 3.9 **	63.8 ± 2.5 **	66.2 ± 5.7 **	91.4 ± 4.6 ***, ††, ##

\* P < 0.05, \*\* P < 0.01, \*\*\* P < 0.001 as compared with control group; † P < 0.05, †† P < 0.01, vs ISO group, # P < 0.05, ## P < 0.01 vs. Chol+ISO group. (n = 6 each group).

**Figure 1.** The Comparison of the LDL and Oxidized LDL Level in the Serum of Rats

\* P < 0.05, \*\*\* P < 0.001 vs. the control group and # P < 0.05, ### P < 0.001 vs. the chol group.

the Malondialdehyde (MDA) level in the myocardial homogenates. Compared to the control healthy group, feeding with both cholesterol and oxidized cholesterol significantly ( $P = 0.031$  and  $P < 0.001$ ) increased the lipid peroxidation in the animals' hearts. Heart MDA level was also increased significantly in all groups which received ISO (MI groups) compared to the control group ( $P < 0.001$ ). However, in the ISO-induced MI groups, elevation in the MDA level in the oxidized Cholesterol-fed animals was significantly ( $P < 0.001$ ) higher than that of Cholesterol-fed group. (Table 1).

#### 4.2. Effects of Cholesterol and Oxidized Cholesterol on Infarct Size

Feeding animals with diets containing cholesterol and oxidized Cholesterol caused a noticeable increase in the myocardial infarct size following myocardial infarction induced by ISO. As shown in Figure 2, the mean infarct size in the heart of rats with ISO-induced MI which were fed with standard diet was  $32.1 \pm 2.9\%$ , while feeding with diets containing cholesterol and specially oxidized Cholesterol increased the size of myocardial infarction significantly up to  $40.33 \pm 2.27\%$  ( $P = 0.045$ ) and  $52.16 \pm 3.8\%$  ( $P = 0.001$ ), respectively. Furthermore, the infarct size in the oxidized Cholesterol-fed group was over 25% larger than the cholesterol-fed group ( $P = 0.005$ ) among animals with MI. In addition,

feeding animals with oxidized cholesterol also caused necrotic injury in the heart tissue even without inducing MI.

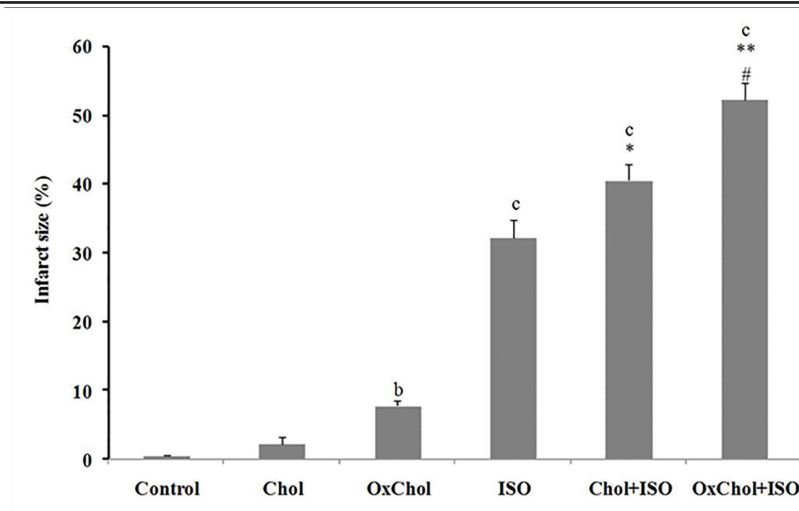
#### 4.3. Effects of Cholesterol and Oxidized Cholesterol on the Heart CoQ10 Content

There was a significant negative correlation between cholesterol and oxidized cholesterol serum levels with CoQ10 content in the heart tissues of both healthy and MI-induced groups. The total CoQ10 concentration in the heart tissue in the control group ( $4.45 \pm 0.19 \mu\text{g}/100\text{mg}$  tissue) was significantly ( $P = 0.001$ ) higher than the cholesterol-fed group ( $2.99 \pm 0.05 \mu\text{g}/100\text{mg}$  tissue) as well as the oxidized cholesterol-fed group ( $1.42 \pm 0.06 \mu\text{g}/100 \text{mg}$  tissue). It was also revealed that the CoQ10 content in the heart tissue was decreased significantly ( $P = 0.001$ ) after MI induction and supplementary cholesterol, and specially oxidized cholesterol in animals' diet increased the susceptibility of the heart tissue to loss of CoQ10 ( $2.89 \pm 0.24$  vs.  $1.6 \pm 0.11$  and  $0.84 \pm 0.07 \mu\text{g}/100\text{mg}$ ,  $P = 0.001$ ) (Figure 3). Additionally, oxidized cholesterol-rich diet significantly ( $P = 0.001$ ) decreased the CoQ10 content compared to cholesterol-rich diet.

#### 4.4. Myocardial CO Q10 Content Correlation with Infarct Size

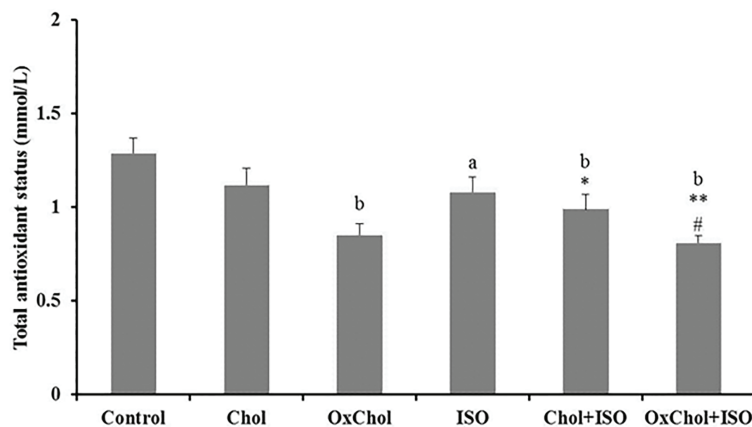
A significant correlation was noted between the coQ10

**Figure 2.** Myocardial Infarct Size as a Percentage of the Total Heart Size



bp < 0.01 vs. the control group; cp < 0.001 vs. the control group; \* P < 0.05, \*\* P < 0.01 vs. the ISO group; # P < 0.05 vs. the Chol+ISO group.

**Figure 3.** CoQ10 Content in the Rats' Heart Tissue



cp < 0.001 vs. the control group; \*\*\* P < 0.001 vs. the ISO group; ## P < 0.01 vs. the Chol+ISO group.

content and infarct size (Figure 4) in the ISO ( $r_2 = 0.7$ ,  $P = 0.037$ ) and oxidized cholesterol fed animals ( $r_2 = 0.66$ ,  $P = 0.049$ ). The same correlation was shown between the Co Q10 content and infarcted size in the cholesterol-fed ( $r_2 = 0.59$ ,  $P = 0.072$ ) group.

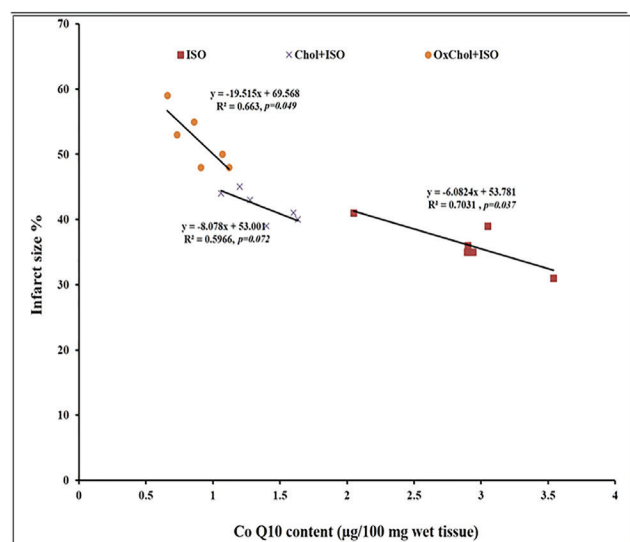
**4.5. Histopathological Examination of the Cardiac Tissues**

Figure 5 illustrates regular arrangement of the myocardial cells with normal pattern in the control group.

Histological examination of cardiac autopsies of the isoproterenol-treated rats revealed prevalent subendocardial necrosis and numerous hyperplasia along with intensified intramuscular edema (Figure 2). It was found that feeding with cholesterol and specially oxidized cholesterol caused a moderate hypertrophy in the cardiomyocytes. Feeding animals with diets containing high amounts of cholesterol and oxidized cholesterol followed by Isoproterenol treatment caused aggravation of necrosis from score 2.2 to 3.1 ( $P < 0.05$ ) and 4 ( $P < 0.01$ ), respectively, as shown in Figure 6.

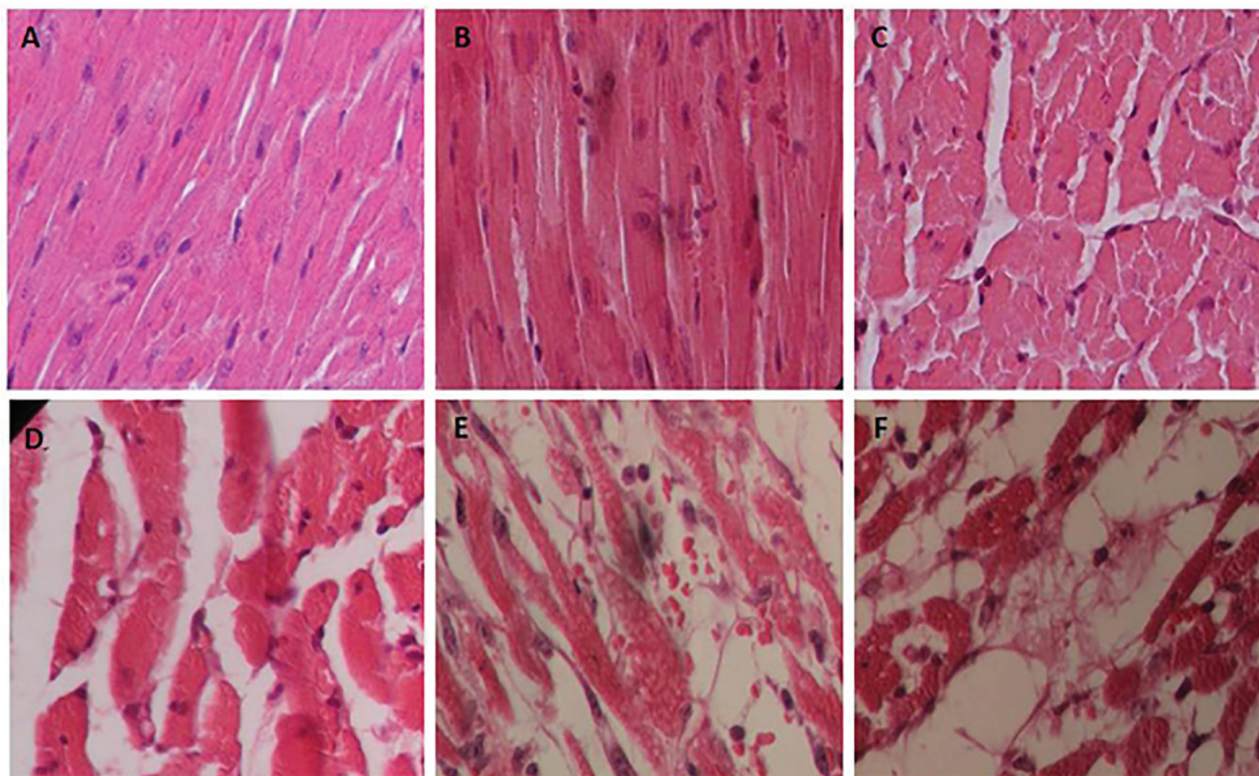
**5. Discussion**

Since the heart is a metabolically active organ and has



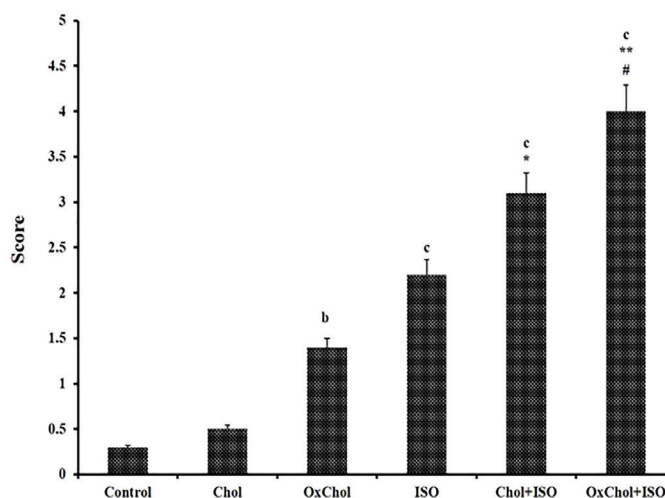
**Figure 4.** Correlation between CoQ10 Content and Infarct Size in Healthy (Control) and Isoproterenol Induced Myocardial Infarction (ISO) in the Rats Fed with Normal Diet, High Cholesterol and High Oxidized Cholesterol-Rich (OxChol) Diets

**Figure 5.** Photomicrographs of the Sections of the Rat Cardiac Apexes. Heart Tissue of a Rat Treated with Isoproterenol (ISO) Shows Intensive Cardiomyocyte Necrosis and Increased Edematous Intramuscular Space.



High LDL and oxidized LDL in the serum following myocardial infarction deteriorates the fibrosis and necrosis. A: Control, B: Cholesterol, C: oxidized cholesterol, D: Isoproterenol, E: Cholesterol+Isoproterenol and F: oxidized cholesterol+Isoproterenol. H and E (40x magnification)

**Figure 6.** Grading of Histopathological Changes in the Rats' Cardiac Apex Tissues



Grades 1, 2, 3, and 4 show low/moderate, high and intensive pathological changes, respectively. ISO: isoproterenol; Chol: Cholesterol; OxChol: oxidized cholesterol. bp < 0.01, cp < 0.001 from respective control value; \* P < 0.05, P < 0.01, \*\*\* P < 0.001 as compared with the isoproterenol treated group and # P < 0.05 as compared with the Chol+ISO group, using one way ANOVA and Student-NewmanKeuls post-hoc test

a large amount of mitochondria because of high energy consumption, it needs a great amount of energy. Therefore, in heart failure and in myocardial infarction, when the heart is highly sensitive to CoQ10 deficiency and energy reserve decreases, lack of CoQ10 as observed in the present study worsens the disease progress. Therefore,

CoQ10 supplementation has the potential for preventing and treating cardiovascular disorders (14, 15). However, in Bimbaum et al.'s study the reduction of the infarct size in the heart of rabbits receiving CoQ10 supplement failed (16). In contrast, a study by Ferrara demonstrated that dietary CoQ10 supplements led to the tissue CoQ10

content elevation and significant suppression of oxidative stress (17). The ingestion of lipid oxidation products may increase the metabolic oxidative stress in vivo. Thus, we proposed that the OxLDL content amplification, through oxidized cholesterol enriched diet or oxidation of LDL in tissues, has a deleterious effect on the myocardium tissue, resulting in infarction size enlargement. This role has been performed not only directly because of increasing oxidative stress, but also through the consumption of CoQ10 and defect in energy metabolism pathway. Although recent studies have established that LDL oxidation occurs in the artery wall to form OxLDL, our findings showed that dietary oxidized cholesterol can also increase OxLDL in the serum. Numerous investigations suggest that the LDL oxidation occurs locally in the tissues such as artery wall, especially in atherosclerotic plaques or during the acute phase of myocardial infarction (18, 19). Another hypothesis is that OxLDL has a dietary origin and oxidized cholesterol and fatty acids can be absorbed and participate in the OxLDL structure (20, 21). Our findings suggest that hypercholesterolemia, and especially high levels of OxLDL, can increase the level of lipid peroxidation both in the normal and infarcted hearts. The oxidative stress induced by ISO was exaggerated in the myocardium of animals with the high serum level of oxidized LDL. Three mechanisms are involved in oxidation facilitation by oxidized cholesterol. First, oxidized cholesterol may have an inhibitory effect on the enzymes that protect lipoproteins from oxidation. The second mechanism is the alteration of lipoproteins structures (oxidized Cholesterol in LDL) so that fatty acids become more susceptible to oxidation. The third probable mechanism is related to the increased antioxidants consumption such as Vitamin E, Vitamin C and CoQ10 following the use of oxidized cholesterol which helps the other pro-oxidants to oxidize the fatty acids or lipoproteins easily (22, 23). Protective effects of these antioxidants against cardiovascular diseases verify this hypothesis (24, 25). Accordingly, administration of lipid-soluble antioxidants also reduces the risk of atherogenesis in animals and increases the resistance of LDL to oxidation in vitro (26, 27).

One potential mechanism by which hypercholesterolemia could induce the cardiac myocyte dysfunction and death is through the mitochondrial function disruption (28, 29). Studies on the cardiomyocyte cells have indicated that oxidized LDL can suppress the mitochondrial respiration and increase the mitochondrial ROS production (30, 31). It is known that the CoQ10 consumption is accelerated by oxidative degradation in the heart, and the increase in CoQ10 biosynthesis is not enough to overcome its consumption by oxidized cholesterol induced oxidative stress. ISO-induced MI causes a severe reduction in the CoQ10 content and a significant increase in the infarction size because of CoQ10 deficiency (32).

### 5.1. Conclusion

Our findings indicated that in animals fed with oxidized cholesterol, the MDA level increased due to the increase in lipid peroxidation. Decreasing the total antioxidant and CoQ10 content in the heart tissue confirms the oxidative

stress increase. Compared to non-oxidized LDL, OxLDL had more deleterious effects on isoproterenol-induced MI and caused more reductive effects on the myocardial content of CoQ10. It seems that CoQ10 supplementation would be useful in prevention and treatment of cardiovascular diseases.

### Acknowledgements

This study was supported by the Research vice chancellor of Tabriz University of Medical Sciences. This article is a part of a thesis submitted for PhD degree (No. 74) in the Faculty of Pharmacy, Tabriz University of Medical Sciences.

### Authors' Contribution

Arash Khorami designed the experiments and prepared the diets; Alireza Gorjani designed the experiments, prepared the materials and wrote the first draft; Nasrin Maleki-Dizaji also drafted the manuscript; Bahador Ghaderi performed the biochemical experiments; and Mojtaba Ziaee did the statistical analysis and revised the manuscript.

### Funding/Support

There is no funding/support.

### Financial Disclosure

All authors declare no competing financial interests exist.

### References

- Ziaee M, Khorrami A, Ebrahimi M, Nourafcan H, Amiraslazadeh M, Rameshrad M, et al. Cardioprotective Effects of Essential Oil of *Lavandula angustifolia* on Isoproterenol-induced Acute Myocardial Infarction in Rat. *Iran J Pharm Res*. 2015;**14**(1):279-89.
- Celermajer DS, Chow CK, Marijon E, Anstey NM, Woo KS. Cardiovascular disease in the developing world: prevalences, patterns, and the potential of early disease detection. *J Am Coll Cardiol*. 2012;**60**(14):1207-16.
- Csont T, Bereczki E, Bencsik P, Fodor G, Gorbe A, Zvara A, et al. Hypercholesterolemia increases myocardial oxidative and nitrosative stress thereby leading to cardiac dysfunction in apoB-100 transgenic mice. *Cardiovasc Res*. 2007;**76**(1):100-9.
- Andreadou I, Iliodromitis EK, Lazou A, Gorbe A, Giricz Z, Schulz R, et al. Effect of hypercholesterolaemia on myocardial function, ischaemia-reperfusion injury and cardioprotection by preconditioning, postconditioning and remote conditioning. *Br J Pharmacol*. 2017;**174**(12):1555-69.
- Osipov RM, Bianchi C, Feng J, Clements RT, Liu Y, Robich MP, et al. Effect of hypercholesterolemia on myocardial necrosis and apoptosis in the setting of ischemia-reperfusion. *Circulation*. 2009;**120**(11 Suppl):S22-30.
- Khorrami A, Ghanbarzadeh S, Ziaee M, Arami S, Andalib S, Maleki-Dizaji N, et al. Effects of LDL and oxidized LDL on cardiac function in isoproterenol-induced myocardial infarction in rat. *Drug Res (Stuttg)*. 2014;**64**(11):576-83.
- Le NA. Lipoprotein-associated oxidative stress: a new twist to the postprandial hypothesis. *Int J Mol Sci*. 2014;**16**(1):401-19.
- Ghanbarzadeh S, Garjani A, Ziaee M, Khorrami A. CoQ10 and L-carnitine attenuate the effect of high LDL and oxidized LDL on spermatogenesis in male rats. *Drug Res (Stuttg)*. 2014;**64**(10):510-5.
- Soraya H, Khorrami A, Garjani A, Maleki-Dizaji N, Garjani A. Acute treatment with metformin improves cardiac function following isoproterenol induced myocardial infarction in rats. *Pharmacol Rep*. 2012;**64**(6):1476-84.
- Staprans I, Pan XM, Rapp JH, Feingold KR. The role of dietary oxidized cholesterol and oxidized fatty acids in the development of atherosclerosis. *Mol Nutr Food Res*. 2005;**49**(11):1075-82.
- Satoh M, Naganuma A, Imura N. Involvement of cardiac metallothionein in prevention of adriamycin induced lipid

- peroxidation in the heart. *Toxicology*. 1988;**53**(2-3):231-7.
12. Khalil PN, Siebeck M, Huss R, Pollhammer M, Khalil MN, Neuhofer C, et al. Histochemical assessment of early myocardial infarction using 2,3,5-triphenyltetrazolium chloride in blood-perfused porcine hearts. *J Pharmacol Toxicol Methods*. 2006;**54**(3):307-12.
  13. Khorrami A, Garjani A, Ghanbarzadeh S, Andalib S. Reduction of coenzyme q10 content: a possible effect of isoproterenol on heart failure and myocardial infarction in rat. *Drug Res (Stuttg)*. 2014;**64**(4):177-81.
  14. Pepe S, Marasco SF, Haas SJ, Sheeran FL, Krum H, Rosenfeldt FL. Coenzyme Q10 in cardiovascular disease. *Mitochondrion*. 2007;**7** Suppl:S154-67.
  15. Sander S, Coleman CI, Patel AA, Kluger J, White CM. The impact of coenzyme Q10 on systolic function in patients with chronic heart failure. *J Card Fail*. 2006;**12**(6):464-72.
  16. Birnbaum Y, Hale SL, Kloner RA. The effect of coenzyme Q10 on infarct size in a rabbit model of ischemia/reperfusion. *Cardiovasc Res*. 1996;**32**(5):861-8.
  17. Ferrara N, Abete P, Ambrosio G, Landino P, Caccese P, Cirillo P, et al. Protective role of chronic ubiquinone administration on acute cardiac oxidative stress. *J Pharmacol Exp Ther*. 1995;**274**(2):858-65.
  18. Ueda M, Ehara S, Kobayashi Y, Naruko T, Shirai N, Hai E, et al., editors. Plaque instability in human coronary atherosclerotic lesions: roles of oxidized LDL and neutrophils. International Congress Series; 2004. Elsevier.
  19. Waddington EI, Croft KD, Sienuarine K, Latham B, Puddey IB. Fatty acid oxidation products in human atherosclerotic plaque: an analysis of clinical and histopathological correlates. *Atherosclerosis*. 2003;**167**(1):111-20.
  20. Hochgraf E, Cogan U, Mokady S. Dietary oxidized linoleic acid enhances liver cholesterol biosynthesis and secretion in rats. *J Nutr Biochem*. 2000;**11**(3):176-80.
  21. Lee H, Chien J, Chen B. Inhibition of cholesterol oxidation in marinated foods as affected by antioxidants during heating. *Food chemistry*. 2008;**108**(1):234-44.
  22. Lapointe A, Couillard C, Lemieux S. Effects of dietary factors on oxidation of low-density lipoprotein particles. *J Nutr Biochem*. 2006;**17**(10):645-58.
  23. Thomas SR, Stocker R. Molecular action of vitamin E in lipoprotein oxidation: implications for atherosclerosis. *Free Radic Biol Med*. 2000;**28**(12):1795-805.
  24. Cirico TL, Omaye ST. Additive or synergetic effects of phenolic compounds on human low density lipoprotein oxidation. *Food Chem Toxicol*. 2006;**44**(4):510-6.
  25. Lotito SB, Frei B. Consumption of flavonoid-rich foods and increased plasma antioxidant capacity in humans: cause, consequence, or epiphenomenon? *Free Radic Biol Med*. 2006;**41**(12):1727-46.
  26. Choy KJ, Deng YM, Hou JY, Wu B, Lau A, Witting PK, et al. Coenzyme Q(10) supplementation inhibits aortic lipid oxidation but fails to attenuate intimal thickening in balloon-injured New Zealand white rabbits. *Free Radic Biol Med*. 2003;**35**(3):300-9.
  27. Neuzil J, Weber C, Kontush A. The role of vitamin E in atherogenesis: linking the chemical, biological and clinical aspects of the disease. *Atherosclerosis*. 2001;**157**(2):257-83.
  28. Pieczenik SR, Neustadt J. Mitochondrial dysfunction and molecular pathways of disease. *Exp Mol Pathol*. 2007;**83**(1):84-92.
  29. Zhu XY, Daghini E, Rodriguez-Porcel M, Chade AR, Napoli C, Lerman A, et al. Redox-sensitive myocardial remodeling and dysfunction in swine diet-induced experimental hypercholesterolemia. *Atherosclerosis*. 2007;**193**(1):62-9.
  30. Ermak N, Lacour B, Druke TB, Vicca S. Role of reactive oxygen species and Bax in oxidized low density lipoprotein-induced apoptosis of human monocytes. *Atherosclerosis*. 2008;**200**(2):247-56.
  31. Kowaltowski AJ, de Souza-Pinto NC, Castilho RF, Vercesi AE. Mitochondria and reactive oxygen species. *Free Radic Biol Med*. 2009;**47**(4):333-43.
  32. Zaa'an MA, Zaki HF, El-Brairy AI, Kenawy SA. Protective effects of atorvastatin and quercetin on isoprenaline-induced myocardial infarction in rats. *Bulletin of Faculty of Pharmacy, Cairo University*. 2013;**51**(1):35-41.